

Histological effect of *Curcuma longa* and *Zingiber officinale* on the liver damage after treatment with hydrogen peroxide in Rats (*Rattus norvegicus*)

Rana Talib Al-Muswie

College of Dentistry, University of Thi qar, Iraq

Email: ranaalmuswie@gmail.com

Eman A. Al-rekab' Noor Ali Badir Al-Asadi

Collage of science' University of Thi qar, Iraq

Abstract

This research is aimed at investigating the hepatotoxic effect of hydrogen peroxide and effects of *Curcuma longa* and *zingiber officinale* on this hepatotoxicity. In present study we administration hydrogen peroxide to animals rat for induced high cholesterol in blood and caused liver damage . These were carried out via estimation of liver function tests and histochange in the liver. Fourteen adult Westar rats *Rattus norvegicus* were used for the experimental investigations. They were grouped into four groups:. Animals in group one served as the control group. Group two consists of rats administered with hydrogen peroxide (1% body weight) .Group three consists of rats administered with hydrogen peroxide and *Curcuma longa* (200 mg/ kg body weight).Group four administered with hydrogen peroxide and *zingiber officinale*(200 mg/ kg body weight). All animals administration orally, the experimental period lasted for 30 days. The rats were sacrificed on the thirteen day. The blood samples collected by cardiac puncture and placed in appropriately labeled bottles for the various assays. And section of liver isolated. There was a decrease in the aspartate aminotransaminase level, alanine aminotransferase level are significantly lower ($P<0.05$) in the rats of the control group than both the rats treated with hydrogen peroxide only and the ones treated peroxide with *Curcuma longa* and peroxide with *zingiber officinale* These were lower in the rats treated with *Curcuma longa* and *zingiber officinale* than the rats treated with hydrogen peroxide alone. These reduction is however not statistically significant and it presents that these could be dosage related. The histological change in the section of liver showed as clusters of inflammatory cells surrounding portal area

or within the parenchyma was seen. Vacuation within hepatocytes and congestion in central vein were observed and was generally necrosis hepatocytes compare compared with animals treatment in extracts a decreasing in degenerative changes was noticed in proxide + curcuma extract, there was a moderate decreasing of hepatocellular damage and portal tract fibrosis, inflammatory infiltration compared to peroxide group .But in the fourth group zingiber +hydrogen peroxide no hepatocellular damage,. It was noticed that this group has the same histological appearance as the control group. These results indicate that hydrogen peroxide is induce to increase the cholestrole and caused hepatotoxic but that *Curcuma longa* and *zingiber officinale* may be a protective effect on this hepatotoxicity.

Keywords: hydrogen peroxide, *Curcuma longa*; *Zingiber officinale*, ALT.; AS., *Rattus norvegicus* ,liver

Introduction

Except for the skin the liver is the body's biggest organ, with a larger right lobe and smaller left lobe (Mischael, 2011). The liver doing many functions like produces most of the body's circulating plasma proteins such as lipoproteins ,Albumins, fibrinogen, glycoproteins, prothrombin, and nonimmune B, α -globulin, also, it is storage and converts several vitamins and Ion(Ross and Pawlina, 2011). From another hand the liver plays an important role of metabolism of the cholesterol in rats (Dietschy *et al.*, 1993).

Although cholesterol is an important element of mammalian cell membranes, excess cellular and circulating cholesterolis harmful and shared to several life-threatening diseases, including coronary artery cardiovascular disease and atherosclerotic (Kratz ., 2005; Williams.,2008). Fatty liver is a situation in which triglyceride vacuoles represent the inside the hepatocytes through steatosis ,that means ,abnormal detention of lipids within a cell. This case is also known as fatty liver disease (FLD). Although there are more than one causes which result in fatty liver,. fatty liver disease is reported to have authenticating with other diseases that affect fat metabolism. Accumulation of fat may also be attendant by a take in progress inflammation of the liver(Zahid *et al.*, 2015). The treatment and control of diseases by the use of available medicinal plants in a locality will continue to play significant roles in medical health care

implications in the developing countries of the world (Akharaiyi, 2010). Muller, (2006), according to the World Health Organization (WHO) study 80% population of world believes in traditional methods of, treatment that is the use of herbal treatment. It is also reported that in comparison to synthetic drugs, herbal medications (Murphy, 1999; Javed *et al.*,2009).

Curcuma longa (Cl) is a rhizomatous perennial herb that back to the family *Zingiberaceae*, is bearing many rhizomes on its root system which are the cause behavior of its culinary spice known as turmeric and its medicinal extract called curcumin. In traditional custom, it has been used for centuries due to its antimicrobial, antitumor, antioxidant properties, anti-inflammatory, and it presents acetylcholinesterase prevents activity The turmeric (Cl) contains three major curcuminoids, namely, demethoxycurcumin, curcumin, and bisdemethoxycurcumin. Curcumin is the most abundant of the three(Bhagavathula, 2009). Many studies have shown the capacity of curcumin to prevent lipid peroxidation, a key process in the onset and progression of many diseases (Srimal.,1997). In an experiment, controlled dosing of turmeric was used to the effects on LDL oxidation was analysed and to feed hypercholesterolemic rabbits. It was found that turmeric extracts efficiently and quickly reduced the levels of cholesterol in the blood along with the occurrence of atherosclerosis with time.

In the another hand *Zingiber officinale* Roscoe (Family: *Zingiberaceae*) familiar known as 'ginger', is a well-known food spice which has also been used traditionally in a wide variety of disorder. Ginger extract has recently been shown to have a variety of biological activities, including anticancer, anti-inflammation, antioxidation, and antimicrobial properties (Fisher-Rasmussen *et al.*, 1991; Sharma *et al.*,1994; Kamtchouing *et al.*, 2002).It was also found to possess a protective against DNA damage induced by hydrogen peroxide H₂O₂.In laboratory animals, ethanol extract of *Zingiber officinale*has been shown to lower plasma lipids in cholesterol fed hyperlipidaemic in rabbits (Bhandari *et al.*,1998; Verma *et al.*, 2004). (Thomson *et al.*,2002), found the aqueous extract of *Zingiber officinale* has also been shown to reduce serum cholesterol and triglycerides. However, in normal rats treated with a whole ginger powder was observed no change in plasma lipids (Akhani.,2004, Sivakumar ., 2004). Liver has certain lipoprotein and cholesterol receptors that recognize the presence of free cholesterol and LDL and take it up for processing

and metabolize it. Liver function tests serve as diagnostic aids when a metabolic process has been disturbed. These include, , aspartate aminotransferase test and alanine aminotransferase test. was used, for alanine transaminase (ALT) and estimation the aspartate transaminase (AST) estimation,

This research is aimed at investigating the hepatotoxic effect of hydrogen peroxide and effects of *Curcuma longa* and *zingiber officinale* on this hepatotoxicity. These were carried out via estimation of liver function tests and histological change in liver.

Materials and Methods

Experimental animals:

This study was conducted at the animals laboratory, Department Biology, Collage of science, Thiqr University. (*Z. officinale*) was purchased from the local market. One kilogram fresh ginger rhizome was cleaned, washed under running tap water, cut into small pieces, air dried and powdered. 40 Adult rat (n=40) were included in the present study. They were 8 weeks old and weighing 28 ± 3 g each. They were obtained from animal house at college of Science, and housed in temperature controlled rooms (25C) with constant humidity (40-70%) and 12h/12h light/ dark cycle prior. All animals were treated in accordance to the principles of laboratory animal care. Thereafter, the rat were randomly divided into four groups, control (n=10) and experimental (n=30) groups. The control group(G1) just received 8ml distilled water daily. However, the experimental groups split into three groups each included ten rat. (G.2) received 1% of hydrogen peroxide ,(G.3) received 200 mg/kg/day of Curcuma and hydrogen peroxide, and (G.4) received Zingiber 200mg/kg/day and hydrogen peroxide 50mg of peroxide dissolved in drinking water for 30 consequence days.

Collection of blood samples:

The rats were sacrificed and put in chloroform and the blood samples collected by cardiac puncture and placed in appropriately labeled bottles for the various assays for aspartate aminotransferase test and alanine aminotransferase test.

Histological Study :

Isolation of Organ:-

After the collection of blood samples from the animals the following organ liver was isolated In brief the routine sequence of events according to (Fisher .,2008).

Statistical Analysis:-

Standard analysis of the data of different studied groups was performed using the computerized statistical program: The SPSS program (Statistical Program for Social Sciences). The results were expressed as mean± S.E. Analysis of variance (ANOVA) was used to compare the results of different groups. The differences are considered to be significant at the level ($P \leq 0.05$).

Results

The alanine aminotransferase (ALT) level in the rats of the control group is significantly lower ($P < 0.05$) in the rats of the control group than both the rats treated with peroxide only. and the ones treated with peroxide +zangber. ALT level of the rats treated of peroxide + zingiber also animals treated with peroxide +curcuma are lower than those treated with peroxide only. The aspartate aminotransaminase (AST) level in the rats of the control group is significantly lower ($P < 0.05$) in the rats of the control group than both the rats treated with hydrogen peroxide only and the ones treated with hydrogen peroxide + *zingiber* and group peroxide +curcuma. However AST level of the rats treated with peroxide + zingiber and peroxide +curcuma are lower than those treated with peroxide only Table(1).

(Table 1):Showing the various hepatic function (liver enzyme)level in the various groups

Animal grou	SGPT(ALT)IU/L	SGOT (AST) IU/L
(G1)Control group	18.00± 0.25 ^c	2.00± 1.18 ^c
G2) hydrogen peroxide	23.83± 1.35 ^b	51.50± 0.39 ^b

G3) <i>Curcuma</i>	20.16± 0.79 ^a	13.00± 1.24 ^a
G4) <i>Zingiber</i>	17.33± 0.33 ^a	17.33± 0.61 ^a
LSD	2	6

Values are means ± S.E.; The different letters refers to significant differences among groups ($P \leq (0.05)$); Same letters refer to no significant differences ($P \leq (0.05)$) $P \leq 0.05$ =statistically significant

Histological Changes

Histopathological studies showed that treatment with hydrogen peroxide caused liver damage including severe centrizonal necrosis ,which was also accompanied by congestion and accumulation of inflammatory cells. In contrast, hepatic necrosis and congestion appeared less marked in *Curcuma longa* and *Zingiber officinale* extracts-treated rat.

No morphological damage was observed in liver of the rats in the control group (figure 1) Light microscopical findings.In the control group, hepatocyte plates were normal and fibrosis, ductal dilatation and proliferation or inflammatory infiltration was not observed. In addition, in the control group, hepatocellular vacuolization was not seen. Degenerative changes in various degrees were observed in microscopic examination of liver in animal group treated with hydrogen peroxide to induced cholesterol and liver damage . In this group, as clusters of inflammatory cells surrounding portal area or within the parenchyma was seen. Cytoplasmic vacuolization within hepatocytes and congestion in central vien were observed and was generally necrosis in some hepatocytes (Fig.2;3). A decreasing in degenerative changes was noticed in peroxide+ curcuma extract in the third group as compared to the peroxide group. There was a moderate decreasing of Hepatocellular damage and portal tract fibrosis, inflammatory infiltration in peroxide+ curcuma compared to peroxide group (Fig 4;5). No hepatocellular damage, portal fibrosis and inflammatory infiltration were found in the fourth group zangberia +peroxide. It

was noticed that this group has the same histological appearance as the control group (Fig.6;7).

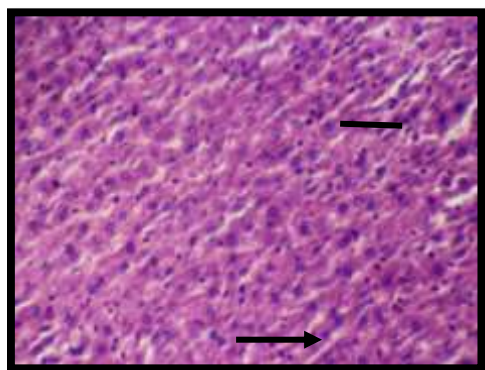


Fig. 1:Section of liver as control group was healthy and within normal limits Sinusoids Hepatocytes

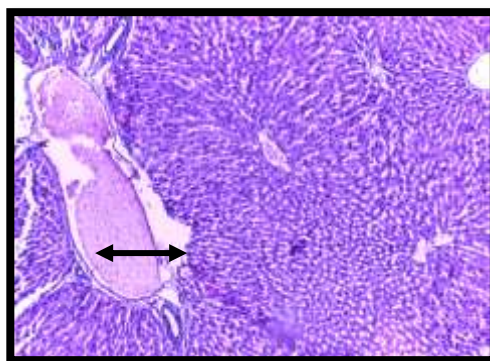


Fig.2 : Section of liver treated with hydrogen peroxide with congestion of central vein and sinusoids , necrosis in some of

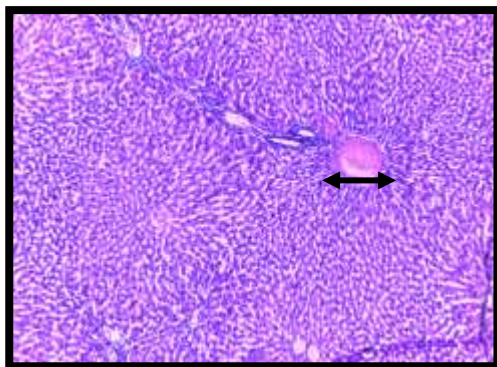


Fig. 3: Section of liver treated with hydrogen peroxide showing congestion of central vein and inflammatory cells infiltration :(Haematoxylin and Eosin stain, 10×)

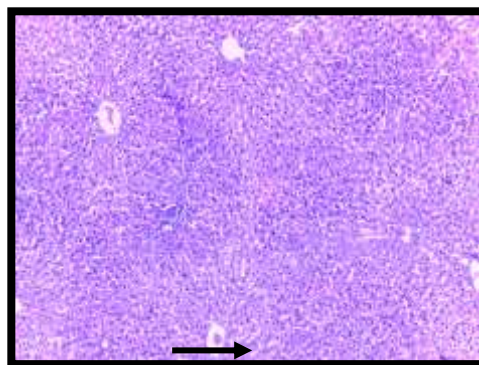


Fig. 4: Section of rat liver tissue treated by peroxide and Curcuma (arrows), accumulation of inflammatory cells and congestion are less than peroxide group. :(Haematoxylin and Eosin stain, 10×)

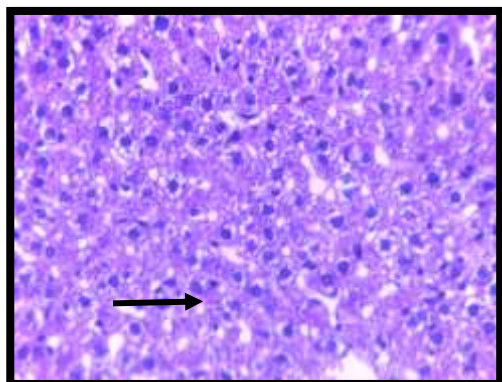


Fig.5 : : Section of rat liver tissue treated with Curcuma and hydrogen peroxide showing inflammatory infiltration were minimal (Haematoxylin and Eosin stain, 40×)

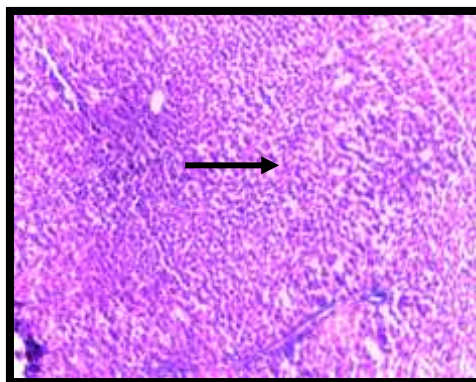


Fig.6 :Section of liver treated with Zingiber officinale and hydrogen peroxide showing minimal inflammatory cells:(Haematoxylin and Eosin stain, 10×)

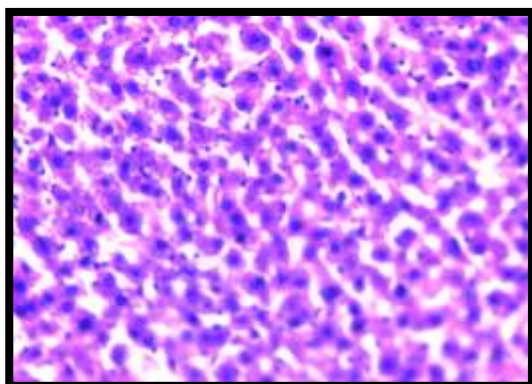


Fig.8:Section of liver treated with Zingiber officinale and hydrogen peroxide .Note the portal area and hepatocyte plates in the Zingiber officinale group showing similar appearance with the control group.(Haematoxylin and Eosin stain, 40×)

Dissection

The results of this study demonstrate that *Curcuma longa* and Zingiber officinale extracts is effective in protecting against the hepatotoxic effects of hydrogen peroxide which caused oxidative stress. The present study found hydrogen peroxide induced high cholesterol in liver and increased liver enzyme , In another study for (Burt ,1993) and Friedman,(1993) showed the biochemical tests acute elevation of serum transaminases (ALT, AST) induced by peroxide significantly reduced in the groups received *Curcuma longa* extract ($p<0.05$),and reduced in the groups received Zingiber officinale extract . Liver necrosis decreased according to normal liver sinusoids are limited by fenestrated endothelial cells Hypercholesterolemia is said to contribute to hepatic injury as a result of Cholestrol accumulation. Lipid accumulation leads to oxidative stress in hepatic tissue. The oxidative stress may contribute to peroxidation of LDL (Britton and Bacon,1994 ;Morel *et al.*,1983) These peroxidative fatty acids and reactive oxygen species induce hepatic damage. Hausner *et al.* showed that cholesterol supplemented diet caused high plasma Chol level with hepatic and adrenal cell degeneration (Hausner *et al.*, 1995). In this report, we showed that the application of curcuma and zangberia extracts markedly prevents acute hepatic failure in a rat model of acute hepatic injury, which was searched at least in part by free radical formation. curcuma and Zingiber officinale administration is a widely used experimental model that mimics the acute liver failure caused by toxic substances (Grzanna *et al.*, 2005; Tanabe.,1993), Although the liver plays a key role in transforming and clearing chemicals, certain medicinal agents, when taken in excess, may injure the organ. Other chemical agents or industrial agents can also induce hepatotoxicity. These chemicals often cause subclinical injury to the liver, increasing liver enzymes., (Ostapowicz.,2002). The opinion of researcher in present study was proven that turmeric and zangber were reduced both the oxidation and circulation of oxidized levels of LDL cholesterol which leads to reduction in the occurrence or treatment of already present atherosclerosis in the subjects. The major problem caused by cholesterol is due to its nature of associating with LDL and circulating in the blood freely. In most cases, when the amount of cholesterol in the body gets high, liver is unable to take up excess of it because of the lack of extra receptors. Also found Riccardi *et al.* , (2007) the effects of the ethanol extract of Zingiber officinale on liver cholesterol and

triglycerides, and hepatic expression of LDL receptor and HMG-CoA reductase mRNA and protein levels in high-fat diet-fed rats, a metabolic model of obesity and dyslipidaemia that simulates human disease. Tanabe *et al*, that an active component in *Zingiber officinale* acts on the liver to decrease cholesterol biosynthesis. Earlier studies have also demonstrated that *Zingiber officinale*, through its activity on hepatic cholesterol-7 α -hydroxylase, stimulates the conversion of hepatic cholesterol to bile acids, an important pathway for cholesterol elimination (Ahmed and Sharma 1997; Srinivasan and Sambaiah, 1991).

Hence, it is important to increase the metabolism of the liver by increasing the reception of cholesterol so that it doesn't circulate freely along with LDL and damage the arteries causing other problems. In previous studies, it was suggested that curcuma and *Zingiber* prevents occurring of atheroma plaques in atherosclerotic lesions. which a potent antioxidant and so they prevents oxidation of polyunsature fatty acids in cell membranes (Prasad and Kalra 1993, . Bieri.,1993). In the present study, decreasing of hepaticfibrosis, and inflammatory infiltration were observed as protective effects of curcuma and *Zingiber officinale* , cell morphology was protected well to Chol toxicity. They have a synergistic effect, so their antioxidant effects increase. Also, the results as the treated group seem to be the same as in the control group. As a result, we can say that, curcuma and *Zingiber officinale* decreases hepatocellular damages and these antioxidant agents have protective effects on hepatocytes. *Zingiber officinale* has been used to control lipid disorders and reported to possess remarkable cholesterol-lowering activity in experimental hyperlipidaemia. Srinivas *et al* .,(2009) found the effect of acharacterized and standardized extract of *Zingiber officinale* on the hepatic lipid levels as well as on the hepatic mRNA and protein expression of reduce-density lipoprotein (LDL) receptor and 3-hydroxy-3-methylglutaryl coenzyme A (HMG-CoA) reductase was investigated in a high-fat diet-fed rat model.

We have conducted this experiment to study the effect of *Curcuma longa* and *Zingiber officinale* against hydrogen peroxide which induced high cholesterol, liver enzyme and liver toxicity . Liver necrosis decreased according to histological observation as shown in Fig. 2, 3 and 4. The

characteristic zone 3 necrosis of acetaminophen appears to be produced by an electrophilic metabolite of drug.

References

Ahmed, R.S; Sharma, S.B. (1997).Biochemical studies on combined effects of garlic (*Allium sativum* Linn) and ginger (*Zingiber officinale*Rosc) in albino rats. *Ind J Exp Biol*;35:841–3.

Akhani, S.P; Viswarkarma, S.L; Goyal, R.K.(2004). Antidiabetic activity of *Zingiber officinale* in streptozotocin-induced type I diabetic rats.*J Pharm Pharmacol*;(56):pp:101–5.

Akharaiyi, F.C.,(2010) .Boboye, B., *J Nat Prod*, (3), :pp:27-34.

Bhagavathula, N.; Warner, R.L; DaSilva, M;McClintock, S.D; Barron, A.; Aslam, M.N, et al. (2009). A combination of curcumin and ginger extract improves abrasion wound healing in corticosteroid-impaired hairless rat skin. *Wound Repair Regen.*;(17):pp:360–6.

Bhandari U, Sharma JN, Zafar R. (1998). The protective action of ethanolic ginger extract in cholesterol-fed rabbits. *J Ethnopharmacol*;61:167–71.

Bieri, J .G ;Corash, L . Hubbard, V. S. (1983).Medical uses of vitamin E. *New Engl J Med* .308:18.

Britton, R . ;Bacon, B .R. (1994). Role of free radicals in liver diseases end hepatic fibrosis. *Hepato-Gastroenterol* 41: 343-348 16. Morel D W, Hessler J R , Chisolm G M. Low density lipoprotein cytotoxicity induced by free radical peroxidation of lipid. *J Lipid Res* 24: 1983.

Burt, A. D.(1993). Cellular and molecular aspects of hepatic fibrosis. *J Pathol* (170): pp:105-114.

Dietschy, J. M ;Turley, S. D; Spady, D. K.(1993).Role of liver in the maintenance of cholesterol and low density lipoprotein homeostasis in different animal species, including humans. *J Lipid Res* 34.

Fischer, A .H. et al. .(2008). Hematoxylin and eosin staining of tissues and cell sections. *Cold Spring Harb. Protoc*10.

Fisher–Rasmussen, W. ;Kjaer, S.; Dahl, C. and Asping, U. (1991). Ginger treatment of Hyperemesis gravidarm. *European Journal of Obstetrics & Gynecology and Reproductive Biology* (38) pp:19–24.

Friedman, S. L.(1993). The Cellular basis of hepatic fibrosis. *New Engl J Med* 308: 25.

Grzanna R, Lindmark L and Frondoza CG (2005). Ginger – An Herbal Medicinal Product with Broad Anti-Inflammatory Actions. *Journal of Medicinal Food* 8(2)pp: 125-132.

Hausner ,E. A ; Schlingmann, K. L ; Chen, H. W; Gillies, P .J ; Kieras ,C. L ; Ross, P. E .; Von Pelt, C. B .S. (1995). Hepatic and adrenal changes in rabbit associated with hyperlipidemia caused by a semisynthetic diet. *Lab Animal Sci* , 45:6.

Javed, I.; Rahman, ZU.; Khan, MZ.; Muhammad, F.; Aslam, B.; Iqbal Z et al.(2009). Antihyperlipidaemic efficacy of Trachyspermum in albino rabbits. *Acta Vet Brno*; (78):pp: 229-36.

Kratz, M. (2005). Dietary cholesterol, atherosclerosis and coronary heart disease. *Handb Exp Pharmacol*;(170) :pp:195–213.

Michael, H. ;Ross, and Wojciech Pawlina, W.(2011).Histology Atex and Atlas with correlated cell and molecular Biology.

Muller, MS.; Mechler, E. (2005). Medicinal Plants in Tropical Countries - Traditional Use, Experience, Facts. Georg Thieme Verlag, Stuttgart, Germany. Pp: 166.

Murphy, JM. (1999). Preoperative considerations with herbal medicines. *Am Org Regist Nurses J*; (69):pp: 173-83.

Ostapowicz,G. Fontana, R.J.; Schiodt, F.V.; Larson, A. Davern,T.J.; Han SH, M. ;Cashland, T.M.; Shakil, A.O.; Hay, J.E.; Hynan ,L. et al. (2002). Results of a prospective study of acute liver failure at 17 tertiary care centers in the United States. *Ann Intern Med*.;137(12):pp:947–54.View Article Pub Med Google Scholar.

Prasad, K.; Kalra, J.(1993). Oxygen free radicals and hypercholesterolemic atherosclerosis: effect of vitamin E. *AmHeart Journal*, (125): pp:958-973,.

Riccardi G, Giacco R, Rivellese AA. (2007). Dietary fat, insulin sensitivity and the metabolic syndrome. *Clin Nutr*;23:447–56.

Sharma, P.K. and Agarwal ,A.A (1996). Role of reactive oxygen species in male infertility. *Urology* (48):pp:835-850.

Sivakumar, V.; Sivakumar, S. (2004).Effect of indigenous herbal compound preparation ‘Trikatu’ on the lipid profiles of atherogenic diet and standard diet fed *Rattus norvegicus*. *Phytother Res*;(18):pp:976–81.

Srimal, R.C. (1997).Turmeric a brief review of medicinal properties. *Phytotherapy* .;(68):pp:483–493.

Srinivas Nammi1; Moon, S. ;Kim1 Navnath, S. ;Gavande George, Q. ;Lil and Basil, D. (2009). RoufogalisRegulation of Low-Density Lipoprotein Receptor and 3-Hydroxy-Methylglutaryl Coenzyme A Reductase Expression by *Zingiber officinale* in the Liver of High-Fat Diet-Fed Rats Journal compilation _ Nordic Pharmacological Society. *Basic & Clinical Pharmacology & Toxicology*, (106):pp: 389–395

Srinivasan, K. Sambaiah, K. (1991). The effect of spices on cholesterol-7 α -hydroxylase activity and on serum and hepatic cholesterollevels in the rat. *Int J Vit Nutr Res*;(61):pp:364–9.

Tanabe, M.; Chen, Y.D.; Saito, K.I.; Kano ,Y. (1993). Cholesterol biosynthesis inhibitory component from *Zingiber officinale* Roscoe. *ChemPharm Bull*;(41):pp:710–3.

Thomson, M.; Al-Qattan, K.K.; Al-Sawan, S.M.; Alnaqeeb, M.A.; Khan, I.; Ali, M. (2002). The use of ginger (*Zingiber officinale* Rosc.) as a potential anti-inflammatory and antithrombotic agent. *Prostaglandins Leukot Essent Fatty Acids*;(67):pp:475–8.

Verma, S.K.; Singh, M.;Jain, P.; Bordia, A. (2004) .Protective effect of ginger, *Zingiber officinale* Rosc on experimental atherosclerosis in rabbits. *Ind J Exp Biol*;(42):pp:736–8.

Williams ,K.J. (2008). Molecular processes that handle and mishandle dietary lipids. *J Clin Invest*;(118):pp:3247–59.

Zahid Iqbal, et al.(2006). inflammation of the liver (hepatitis), called steatohepatitis . Fatty liver disease and fatty acid oxidation. *Am J Physiol Gastrointest Liver*

التأثير النسيجي للكرم والزنجبيل على ضرر الكبد بعد المعاملة ببيروكسيد الهيدروجين في الجرذ (*Rattus norvegicus*)

رنا طالب الموسوي¹ إيمان علي الركابي² نور علي بدر الاسدي³

كلية طب الاسنان¹ كلية العلوم^{2,3} جامعة ذي قار \ العراق

Email: ranaalmuswie@gmail.com

الخلاصة

تهدف الدراسة الحالية لمعرفة تأثير بيروكسيد الهيدروجين على سمية الكبد وتأثير مستخلصات الكرم والزنجبيل على هذه السمية. في هذه الدراسة جرعت الحيوانات الجرذ من بيروكسيد الهيدروجين ليرفع من مستوى الكوليسترول بالدم والذي يسبب ضرر في الكبد، وكان ذلك عن طريق تقييم وظائف الكبد والتغيرات النسيجية. 40 حيوان من الجرذ البيضاء البالغة استخدمت في التجربة وقسمت إلى أربعة مجاميع استخدمت المجموعة الأولى كمجموعة سيطرة. المجموعة الثانية جرعت ببيروكسيد الهيدروجين 1% من وزن الجسم، المجموعة الثالثة جرعت 200 ملغم \ كغم يوميا من بيروكسيد الهيدروجين ومستخلص الكرم أما المجموعة الرابعة فقد أعطيت بيروكسيد الهيدروجين ومستخلص الزنجبيل 200 ملغم/كغم يوميا. كل الحيوانات جرعت فمويا ولمدة 30 يوما. شرحت الحيوانات بعد ذلك وأخذت عينة الدم وعزل نسيج الكبد، كان هناك نقصان في مستوى انزيمات الكبد ALT, AST في مجموعة السيطرة وكان هنالك فرق معنوي $P \leq 0.05$ عند مقارنتها بمجموعة البيروكسيد فقط والمجاميع الأخرى للبيروكسيد مع الكرم ومع الزنجبيل. كذلك وجد هنالك فرق معنوي في انخفاض مستوى الأنزيمات في المجموعة الثالثة والرابعة عن المجموع الثانية $P \leq 0.05$. نجد في المقاطع النسيجية للكبد عناقيد من الخلايا الالتهابية تحيط في منطقة المدخل كذلك لوحظ تفجى للخلايا الكبدية واحتقان الوريد المركزي وحدثت تنخر لبعض الخلايا في الحيوانات التي جرعت ببيروكسيد الهيدروجين فقط. مقارنة مع الحيوانات المعاملة بينما الحيوانات التي جرعت بالبيروكسيد مع الكرم نلاحظ تغيير طفيف في الخلايا الكبدية وترشح قليل للخلايا الالتهابية مقارنة مع مجموعة السيطرة وكذلك عند مقارنتها بالمجموعة التي جرعت بالبيروكسيد فقط، لكن نجد في المجموعة الرابعة، البيروكسيد مع الزنجبيل ليس هنالك تغييرات للخلايا الكبدية وكانت الملاحظة لهذه المجموعه وكأنه تظهر مجموعة سيطرة. تلك النتائج تشير إلى إن بيروكسيد الهيدروجين يسبب في ارتفاع الكوليسترول والذي يؤدي ضرر للكبد لكن مستخلصات الكرم والزنجبيل تحمي من هذه السمية للكبد.